

Arthroscopic Debridement and Closed Pinning for Chronic Dynamic Scapholunate Instability

Nickolaos A. Darlis, MD, Robert A. Kaufmann, MD,
Filippos Giannoulis, MD, Dean G. Sotereanos, MD

From the Department of Orthopaedic Surgery, Allegheny General Hospital, Pittsburgh, PA; and the Department of Orthopaedic Surgery, University of Pittsburgh Medical Center, Pittsburgh, PA.

Purpose: For chronic dynamic scapholunate (SL) instability (>3 months after injury) open procedures (capsulodesis, limited intercarpal fusions, tenodesis, SL ligament reconstruction) have become popular in recent years but their long-term results have been suboptimal. We evaluated retrospectively the results of aggressive arthroscopic debridement of the SL ligament to bleeding bone in an effort to induce scar formation and closed pinning of the SL joint in patients unwilling to have an open procedure.

Methods: Eleven patients (mean age, 37 y) presenting with persistent posttraumatic pain and weakness to the wrist were diagnosed with dynamic SL instability (positive Watson scaphoid shift test result, SL gapping on grip-view radiographs, arthroscopic findings of a Geissler grade III or IV SL tear) and treated. Range of motion, grip strength, radiographic measurements, and the Mayo wrist score were used to evaluate the results.

Results: The mean follow-up period was 33 months (range, 12–76 mo). Three patients had subsequent surgery 9 to 11 months after the procedure. Subsequent surgeries included a dorsal capsulodesis, a four-corner fusion, and a wrist arthrodesis. Of the 8 remaining patients there were 2 excellent, 4 good, 1 fair, and 1 poor result based on the Mayo wrist score. In these patients the mean range of motion was 65° of extension to 59° of flexion and the mean grip strength was 82% of the uninjured contralateral extremity. Although persistent radiographic SL gapping in grip views was noted in all 8 patients none progressed to static instability or dorsal intercalated segment instability.

Conclusions: The results of this technique are suboptimal; however, it may be an option for patients unwilling to have more than an arthroscopic procedure or those requiring maintenance of wrist motion, provided they understand the risks and benefits of this approach. (*J Hand Surg* 2006;31A:418–424. Copyright © 2006 by the American Society for Surgery of the Hand.)

Type of study/level of evidence: Therapeutic, Level IV.

Key words: Arthroscopic debridement, chronic dynamic scapholunate instability, chondrodesis, closed pinning.

Since the first description by Taleisnik¹ in 1980 dynamic scapholunate (SL) instability has been considered a difficult and controversial clinical problem. For chronic dynamic SL instability (treated >3 months after injury) open procedures have become popular. Capsulodesis,^{2–10} limited intercarpal fusions,^{11–17} tenodesis procedures,^{18–20} and SL ligament reconstruction²¹ all have been used in the treatment of this entity. No single procedure has been shown to be extremely effective for dynamic SL

instability or has been adopted universally by surgeons for its treatment.²² To complicate the issue further the clinical definition of dynamic SL instability varies between different reports, making comparisons difficult.

Arthroscopic management of dynamic SL instability generally is considered effective only in acute injuries (<3 months' duration).^{23,24} This notion is supported mainly by a study by Whipple²⁵ published in 1995. That study showed that more than 3 months'

duration of symptoms and more than 3 mm of side-to-side SL gap difference were negative prognostic factors for the success of arthroscopic management and percutaneous pinning for SL instability. The study did not discern if the chronicity of the lesion (>3 months' duration) or its static nature (>3 mm side-to-side SL gap difference) was responsible for the failures. This article evaluates the results of an arthroscopic technique for the treatment of chronic (>3 months after injury) dynamic (no side-to-side difference on plain radiographs, gapping on the affected side with grip-view radiographs) SL instability. The technique consists of aggressive arthroscopic debridement of the torn SL ligament down to bleeding bone and closed pinning of the SL interval. We identified and retrospectively reviewed 11 patients with chronic dynamic SL instability who at the time of treatment were unwilling to have an open procedure and were treated initially with aggressive arthroscopic debridement and closed pinning. The results of this approach are presented.

Materials and Methods

A retrospective review of the senior author's records from 1993 to 2003 found 13 patients with chronic dynamic SL instability who were unwilling to have an open procedure and were treated initially with aggressive arthroscopic debridement and closed pinning. Two of these patients were lost to follow-up evaluation, leaving 11 patients with a mean age of 37 years (range, 23–50 y); there were 8 men and 3 women. The mean time from injury to surgical treatment was 7 months (range, 4.5–10.0 mo). The chief complaints for all patients were weakness and persistent pain with loading the wrist. The diagnosis of dynamic SL instability was based on clinical examination (all patients had pain with Watson scaphoid shift test; in addition 5 of them had a palpable clunk unilaterally) and radiographic findings (symmetric SL interval on posteroanterior [PA] radiographs and gapping of the SL interval on grip-view PA radiographs) (Fig. 1) and was verified by findings of a Geissler grade III or grade IV SL instability²⁶ during arthroscopy. Preoperative PA radiographs in neutral, grip-view PA radiographs, and lateral radiographs were available for all patients. Preoperative magnetic resonance imaging was performed in 9 of the patients and showed an SL interosseous ligament tear in 8. Demographic and preoperative assessment data for the patients are shown in Tables 1 and 2.

Surgical Technique

Wrist arthroscopy was performed by using a standard technique with the arm supported by a tower distraction device and 4.5 to 6.7 kg of distraction applied to

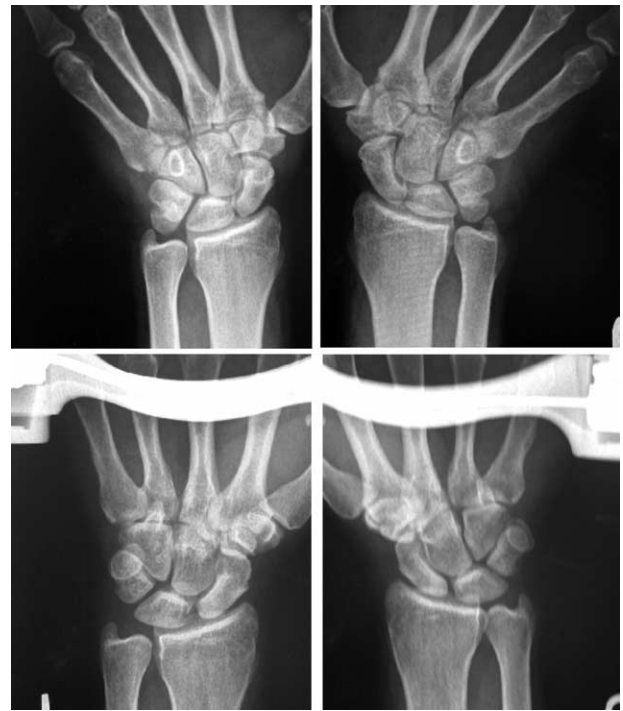

Figure 1. Comparative PA neutral (top) and grip-view (bottom) radiographs of patient 8. The patient is grasping a dynamometer on the grip-view radiographs. Dynamic SL instability is shown on the left wrist with SL interval gapping on the grip-view radiographs compared with the uninvolved right wrist.

the wrist. The 3-4 portal was used for viewing, the 6U portal for outflow, and the 4-5 and 6R portals for instrumentation. The wrist was examined from radial to ulnar (Fig. 2A) and the SL interval stability was examined by inserting the probe into the joint. An attempt to pass the arthroscope through the SL interval (drive-through sign) was made to measure the degree of instability (Fig. 2B). Scapholunate tears were categorized in Geissler and Freeland's²⁶ arthroscopic classifications of wrist interosseous ligament instability. In this study all tears were found to be Geissler grade III (instability permitting a probe to pass between the scaphoid and the lunate) and Geissler grade IV (instability permitting a 2.7-mm arthroscope to pass between the scaphoid and the lunate) (Fig. 2B). During arthroscopy 5 Geissler grade III and 6 Geissler grade IV SL tears were identified and treated. No Geissler grade I (redundancy of the ligament) or grade II (partial SL tear with stable SL interval) tears were identified. The assessment of SL interval stability was performed through a midcarpal portal as well in the 5 patients with Geissler grade III tears. After the SL tear was identified and graded aggressive arthroscopic debridement with a 3.5-mm mechanical shaver was performed. All residual interosseous ligament tissue was removed from both the lunate and the scaphoid and the cartilage of the

Table 1. Patient Data

Patient Number	Age (y)	Follow-Up Time (mo)	Time From Injury (mo)	Geissler Type	Mayo Wrist Score*	Flexion-Extension Arc* (°)	% Grip Strength*
1	26	34	7.0	III	Failure (dorsal capsulodesis 9 mo after surgery)		
2	42	27	9.0	IV	Failure (wrist arthrodesis 11 mo after surgery)		
3	48	29	10.0	IV	60	60	57
4	35	54	7.0	IV	80	140	78
5	37	76	6.0	III	85	140	76
6	23	44	4.5	III	90	135	87
7	40	58	9.0	IV	Failure (four-corner arthrodesis 10 mo after surgery)		
8	50	12	5.0	IV	90	105	110
9	27	20	7.0	III	85	140	82
10	36	26	6.0	IV	75	125	78
11	42	18	7.5	III	85	150	92
Average	36.9	36.2	7.1	—	81.3	124.4	82.5

*Measurements recorded at the final follow-up evaluation.

apposing surfaces of the scaphoid and the lunate were debrided to bleeding bone in an effort to induce scar formation that could stabilize the SL interval (Figs. 2C,D). Additional arthroscopic findings include a central triangular fibrocartilage complex tear that was debrided to a stable rim in 1 patient and a chondral flap of the scaphoid in another patient. Next the arm was removed from the distraction tower and fluoroscopy was brought in. Under fluoroscopic control two 1.4-mm (0.045-in) K-wires were driven from radial to ulnar across the SL joint in all patients. Subsequently the scaphocapitate joint was pinned in the same fashion with 1 (7 patients) or 2 K-wires (4 patients) (Fig. 3).

The wrist was immobilized in a short-arm splint, which was replaced by a short-arm cast in 2 weeks. The patients remained in a short-arm cast until K-wire removal. K-wires were removed at a mean of 9.6 weeks (range, 8–4 wk) after the initial procedure. After K-wire removal range-of-motion exercises and strengthening were permitted and full activities were resumed as tolerated.

In the course of follow-up evaluation (mean, 33 mo; range, 12–76 mo) there were 3 revision surgeries. Three patients had surgery at 9, 10, and 11 months after the initial procedure (Table 1). All 3

patients complained of persistent constant pain. One patient had dorsal capsulodesis and another had four-corner fusion. The third patient developed SL advanced collapse stage III arthritis of the wrist and was treated with wrist arthrodesis because he opted for a definite solution for the pain.

The office charts and preoperative and postoperative radiographs of all patients were reviewed. At final follow-up evaluation new radiographs (PA in neutral, grip-view PA, lateral views) were obtained. The SL gap on the PA views and the SL angle on the lateral views were measured in all preoperative and final follow-up radiographs. The radiographs were scrutinized for evidence of joint-space narrowing or sclerosis indicating arthritis. Preoperative and postoperative clinical examination included measurements of the wrist range of motion with a goniometer. Grip strength was measured as the average of 3 attempts using a hydraulic dynamometer (Jamar; Sammons Preston, Bolingbrook, IL) and was compared with the uninjured contralateral extremity (not corrected for hand dominance). Moreover the patients' preoperative and postoperative pain and occupational statuses were assessed in the context of the Modified Mayo wrist score²⁷ and the score was calculated and rated. Statistical analysis was performed

Table 2. Range of Motion, Grip Strength, and Modified Mayo Wrist Score at Presentation and at the Final Follow-Up Evaluation

Parameter*	Flexion (°)	Extension (°)	Ulnar Deviation (°)	Radial Deviation (°)	% Grip Strength	Mayo Wrist Score
Before surgery†	65 (40–80)	71 (40–90)	26 (15–45)	17 (5–30)	68‡ (42–88)	60‡ (35–75)
After surgery§	59 (30–70)	65 (30–80)	22 (15–40)	14 (5–30)	82‡ (57–110)	81‡ (60–90)

*All measurements presented as mean (range).

†Preoperative values of 11 patients included in the study

‡Values with statistically significant difference.

§Final follow-up values of the 8 patients without revision surgery.

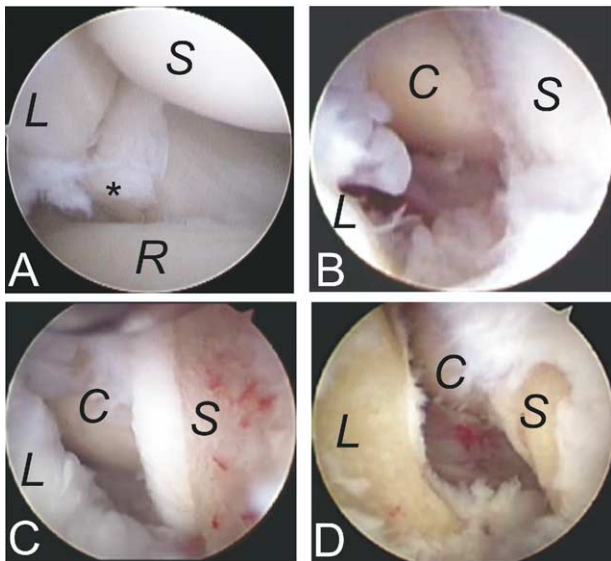


Figure 2. Arthroscopic images of the same patient as in Figure 1 (patient 8). (A) View from the 3-4 radiocarpal portal: a complete SL ligament tear can be seen with remnants of the ligament (*) attached to the lunate. (B) Arthroscopic drive-through sign (Geissler grade IV instability). The arthroscope can be driven through the SL interval from the radiocarpal joint and the head of the capitate can be seen. (C) Arthroscopic debridement with this technique includes the remnants of the SL ligament and the cartilage from the apposing surfaces of the scaphoid and the lunate. The cartilage is taken down to bleeding bone in an effort to induce scar formation that could stabilize the SL interval. (D) View of the SL interval at the end of arthroscopic debridement. S, scaphoid; L, lunate; R, radius; C, capitate.

using the Student *t* test to compare the preoperative and postoperative values in patients who did not have additional surgery and differences in patients with Geissler grade III and grade IV tears; *p* values less than .05 were considered statistically significant.

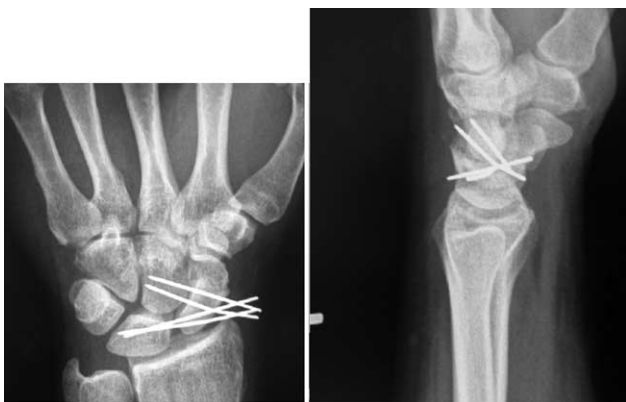

Figure 3. (A) Posteroanterior and (B) lateral radiographs of the same patient as in Figures 1 and 2 (patient 8) showing the placement of 1.4-mm K-wires across the SL and scaphocapitate intervals. Note the absence of a dorsal intercalated segment instability deformity on the lateral radiograph.

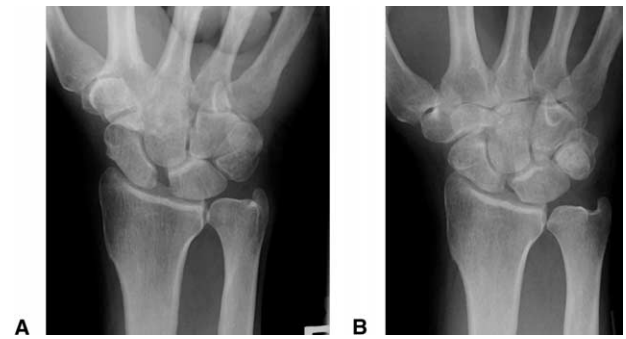

Figure 4. (A) Preoperative PA grip-view radiograph and (B) PA grip-view radiograph at 44 months after surgery of patient 6. Although gapping of the SL interval still can be seen the patient is symptom free and no arthritic changes to the wrist are noted.

Results

Of the 11 patients included in the study 3 had revision surgery and are listed as failures (Table 1). The 8 remaining patients had a mean follow-up period of 34.8 months. The postoperative range-of-motion, grip-strength, and Mayo wrist score data are presented in Table 2 and are compared with preoperative values. Statistical analysis yielded significant differences in grip strength ($p = .001$) and Mayo wrist score ($p < .001$) but not in range-of-motion data.

With regard to radiographic appearance, on preoperative neutral PA radiographs the mean SL interval measured 1.6 mm and was symmetric to the contralateral uninjured extremity. Grip-view radiographs showed gapping at the SL interval to a mean of 2.8 mm on the affected extremity (Fig. 1). Preoperative lateral radiographs showed the absence of a dorsal intercalated segment instability deformity with an SL angle of less than 60° in all patients (mean, 47° ; range, 38° – 60°). No signs of arthritis were observed before surgery. At the latest follow-up evaluation the mean SL gap on the neutral PA views was 1.9 mm and on the clenched-fist wrist PA views it was 2.4 mm (Fig. 4). The mean postoperative SL angle on the lateral view was 53° (range, 40° – 64°). No radiologic signs of arthritis were observed in any of those 8 patients at final follow-up evaluation.

Based on the modified Mayo wrist score²⁷ 2 excellent, 4 good, 1 fair, and 1 poor result were recorded in addition to the 3 patients who are listed as failures because they required revision surgery. All 6 patients with good or excellent scores experienced pain relief, with 4 patients completely pain free and 2 with occasional mild pain. The 2 patients with the fair and poor results both continued to complain of pain in their everyday activities and decreased grip strength but declined further treatment. Other than failures, complications included 2 pin track infec-

Table 3. Comparison of Results (Mean Values) Between Patients With Geissler Grade III and Geissler Grade IV Tears in Arthroscopy

Geissler Type	Age (y)	Follow-Up Period (mo)	Mayo Wrist Score	Flexion-Extension Arc (°)	% Grip Strength
III	31	38	86	143	84
IV	41.8	34	76	107	80

tions that were treated with pin removal and oral antibiotics. No other complications occurred.

An attempt was made to compare patients diagnosed with Geissler grade III tears during arthroscopy with the patients with Geissler grade IV tears (Table 3). Geissler grade III tears were associated with younger patient age at presentation and patients achieved better final wrist scores, ranges of motion, and grip strengths. With the available sample size, however, none of these differences reached statistical significance.

Discussion

The treatment of late-presenting dynamic SL instability remains controversial. Several open procedures have been described but the optimal solution for this problem has yet to be determined. Dorsal capsulodesis has become a popular solution in recent years; unfortunately the long-term results remain suboptimal. After the original encouraging results reported by Blatt² and Lavernia et al³ longer-term follow-up studies indicated that as many as 20% of patients complained of persistent pain after capsulodesis^{6,7,10} and that as many as 20% needed further surgical procedures for the persistent pain.^{5,8} In a study by Moran et al,¹⁰ of 31 patients only 9 achieved good or excellent results. Furthermore there was an average 20° loss of flexion, which appears to be the same for both the original Blatt procedure and for the modified Mayo procedure.¹⁰ In a study by Wintman et al⁴ the results of capsulodesis for dynamic SL instability were more optimistic but the definition of dynamic instability in that report is obscure because 16 of the 20 wrists included did not have widening of the SL interval on the clenched-fist or ulnar-deviation radiographs.

Limited intercarpal arthrodesis is another option for these patients. Scaphotrapezio-trapezoid arthrodesis, which was popularized originally for this indication, has been shown to produce considerable loss of motion from 15% to 45% in all planes,¹³ high complication rates, and development of radiocarpal arthrosis in the long term.^{14,15} Scaphocapitolunate arthrodesis¹⁶ similarly had moderate success. Attempts at scapholunate arthrodesis^{11,12,17} have resulted in highly unpredictable rates of fusion although its proponents claim that most patients obtained pain relief. This was attributed to fibrous union or a chondrodesis effect at the SL interval. This principle of chondrodesis also could be applicable

to the technique of arthroscopic debridement and closed pinning described in this article.

Several tenodesis procedures have been described in an attempt to stabilize the SL interval dynamically. The technique of using a slip of the flexor carpi radialis tendon that is transferred dorsally through a hole at the distal pole of the scaphoid^{18,19} presented initial encouraging results but long-term results are not available. More recently the results of the so-called dynodesis procedure—which consists of transferring a slip of the extensor carpi radialis longus tendon volarly to the flexor carpi radialis through a drill hole at the distal pole of the scaphoid—have been optimistic, with 75% of patients achieving a good or excellent result.²⁰ In that study approximately half of the patients had a Geissler grade I or II instability, which indicates mild (if any) instability. It should be noted that all the patients in our study had Geissler grade III or IV tears and all had gapping on PA grip-view radiographs. Finally, an autograft bone–retinaculum–bone SL ligament reconstruction²¹ provided good initial results, with 12 of the 14 patients treated for dynamic instability experiencing improvement of their pain, but these results have yet to be confirmed by other investigators.

Arthroscopic debridement of partial SL tears^{28,29} yielded satisfactory results in patients without dynamic instability. Arthroscopic debridement alone for complete SL tears was less successful (67% of patients reporting symptomatic relief at a mean follow-up period of 27 months)²⁹ but the resultant instability was not graded in that study. Diagnostic arthroscopy and percutaneous pinning of the SL interval for SL instability was performed by Whipple²⁵ and the results were summarized in his 1995 article. It should be noted that arthroscopic debridement was not attempted in that report and only percutaneous pinning was used. The results of that report indicated that chronicity (>3 months from the injury) in conjunction with static instability (>3-mm SL gap compared with the contralateral healthy extremity) were negative prognostic factors for the success of closed pinning; only 53% of patients with both factors obtained pain relief.

Late (>3 months after injury) arthroscopic debridement and closed pinning was found to be only moderately successful for dynamic SL instability in

this study. Only 6 of the 11 patients achieved a good or excellent result without revision surgery. In the 8 patients who did not have a second procedure, however, the range of motion was maintained satisfactorily, and although persistent gapping of the SL interval was noted on the grip-view radiographs the patients did not progress to static SL instability or dorsal intercalated segment instability deformity and did not show signs of arthritis after a mean follow-up period of 34.8 months. A longer follow-up period is necessary to assess if these benefits are maintained in the long term. Patients with Geissler grade III tears were younger and achieved better final wrist scores compared with patients with Geissler grade IV tears, although with the sample size available these differences did not reach statistical significance. We currently prefer a Geissler grade III tear as a better indication for this procedure.

Among the patients listed as failures (Table 1) 1 (patient 2) had rapid deterioration to arthritis within 11 months after surgery. This patient presented with a severely unstable (Geissler grade IV) SL interval and the arthritis progressed in an SL advanced collapse pattern. We believe that the rapid deterioration can be attributed to an accelerated progression of the natural history of the lesion in this self-employed construction worker, who continued to work through the rehabilitation period.

Chronic dynamic SL instability remains an unsolved problem. There still is no optimal procedure for this problem and the results of arthroscopic debridement and closed pinning presented here are certainly suboptimal as well. This is an approach, however, that does not preclude further open procedures and its morbidity has been minimal. It remains an option for patients who do not wish to proceed with an open procedure or who require maintenance of wrist motion. Patients should understand the risks and benefits of this approach and be prepared to have further surgery if needed.

Received for publication July 17, 2005; accepted in revised form December 28, 2005.

No benefits in any form have been received or will be received from a commercial party related directly or indirectly to the results of this article.

Corresponding author: Dean G. Sotereanos, MD, Allegheny General Hospital, Department of Orthopaedic Surgery, 1307 Federal St, Pittsburgh, PA 15212; e-mail: dsoterea@wpahs.org.

Copyright © 2006 by the American Society for Surgery of the Hand
0363-5023/06/31A03-0010\$32.00/0
doi:10.1016/j.jhss.2005.12.015

References

1. Taleisnik J. Post-traumatic carpal instability. *Clin Orthop* 1980;149:73–82.
2. Blatt G. Capsulodesis in reconstructive hand surgery. Dorsal capsulodesis for the unstable scaphoid and volar capsulodesis following excision of the distal ulna. *Hand Clin* 1987;3:81–102.
3. Lavernia CJ, Cohen MS, Taleisnik J. Treatment of scapholunate dissociation by ligamentous repair and capsulodesis. *J Hand Surg* 1992;17A:354–359.
4. Wintman BI, Gelberman RH, Katz JN. Dynamic scapholunate instability: results of operative treatment with dorsal capsulodesis. *J Hand Surg* 1995;20A:971–979.
5. Uhl RL, Williamson SC, Bowman MW, Sotereanos DG, Osterman AL. Dorsal capsulodesis using suture anchors. *Am J Orthop* 1997;26:547–548.
6. Deshmukh SC, Givissis P, Belloso D, Stanley JK, Trail IA. Blatt's capsulodesis for chronic scapholunate dissociation. *J Hand Surg* 1999;24B:215–220.
7. Muermans S, De Smet L, Van Ransbeeck H. Blatt dorsal capsulodesis for scapholunate instability. *Acta Orthop Belg* 1999;65:434–439.
8. Busse F, Felderhoff J, Krimmer H, Lanz U. Scapholunate dissociation: treatment by dorsal capsulodesis. *Handchir Mikrochir Plast Chir* 2002;34:173–181.
9. Szabo RM, Slater RR Jr, Palumbo CF, Gerlach T. Dorsal intercarpal ligament capsulodesis for chronic, static scapholunate dissociation: clinical results. *J Hand Surg* 2002;27A:978–984.
10. Moran SL, Cooney WP, Berger RA, Strickland J. Capsulodesis for the treatment of chronic scapholunate instability. *J Hand Surg* 2005;30A:16–23.
11. Howard FM, Fahey T, Wojcik E. Rotatory subluxation of the navicular. *Clin Orthop* 1974;104:134–139.
12. Hastings DE, Silver RL. Intercarpal arthrodesis in the management of chronic carpal instability after trauma. *J Hand Surg* 1984;9A:834–840.
13. Watson HK, Ryu J, Akelman E. Limited triscaphoid intercarpal arthrodesis for rotatory subluxation of the scaphoid. *J Bone Joint Surg* 1986;68A:345–349.
14. Kleinman WB, Carroll C 4th. Scapho-trapezio-trapezoid arthrodesis for treatment of chronic static and dynamic scapholunate instability: a 10-year perspective on pitfalls and complications. *J Hand Surg* 1990;15A:408–414.
15. Fortin PT, Louis DS. Long-term follow-up of scaphoid-trapezium-trapezoid arthrodesis. *J Hand Surg* 1993;18A:675–681.
16. Rotman MB, Manske PR, Pruitt DL, Szerzinski J. Scaphocapitolunate arthrodesis. *J Hand Surg* 1993;18A:26–33.
17. Zubairy AI, Jones WA. Scapholunate fusion in chronic symptomatic scapholunate instability. *J Hand Surg* 2003;28B:311–314.
18. Brunelli GA, Brunelli GR. A new technique to correct carpal instability with scaphoid rotary subluxation: a preliminary report. *J Hand Surg* 1995;20A:S82–S85.
19. Van Den Abbeele KL, Loh YC, Stanley JK, Trail IA. Early results of a modified Brunelli procedure for scapholunate instability. *J Hand Surg* 1998;23B:258–261.
20. Seradge H, Baer C, Dalsimer D, Seradge A, Shafi RA, Parker W. Treatment of dynamic scaphoid instability. *J Trauma* 2004;56:1253–1260.
21. Weiss AP. Scapholunate ligament reconstruction using a bone-retinaculum-bone autograft. *J Hand Surg* 1998;23A:205–215.
22. Zarkadas PC, Gropper PT, White NJ, Perey BH. A survey of the surgical management of acute and chronic scapholunate instability. *J Hand Surg* 2004;29A:848–857.
23. Ruch DS, Smith BP. Arthroscopic and open management of dynamic scaphoid instability. *Orthop Clin North Am* 2001;32:233–240.

24. Walsh JJ, Berger RA, Cooney WP. Current status of scapholunate interosseous ligament injuries. *J Am Acad Orthop Surg* 2002;10:32–42.
25. Whipple TL. The role of arthroscopy in the treatment of scapholunate instability. *Hand Clin* 1995;11:37–40.
26. Geissler WB, Freeland AE. Arthroscopically assisted reduction of intraarticular distal radial fractures. *Clin Orthop* 1996;327:125–134.
27. Cooney WP, Bussey R, Dobyns JH, Linscheid RL. Difficult wrist fractures. Perilunate fracture-dislocations of the wrist. *Clin Orthop* 1987;214:136–147.
28. Ruch DS, Poehling GG. Arthroscopic management of partial scapholunate and lunotriquetral injuries of the wrist. *J Hand Surg* 1996;21A:412–417.
29. Weiss AP, Sachar K, Glowacki KA. Arthroscopic debridement alone for intercarpal ligament tears. *J Hand Surg* 1997; 22A:344–349.