

Step-Cut Distal Ulnar–Shortening Osteotomy

Nickolaos A. Darlis, MD, Italo C. Ferraz, MD,
Robert W. Kaufmann, MD, Dean G. Sotereanos, MD, Pittsburgh, PA

Purpose: Several techniques for ulnar-shortening osteotomies have been described in recent years, reflecting the difficulties that sometimes are encountered in what seems to be a relatively simple procedure. We describe the use of a simple step-cut ulnar-shortening osteotomy stabilized with a lag screw and a palmarly placed 3.5-mm neutralization plate.

Methods: Twenty-nine patients had the surgery. The indication was ulnar-impaction syndrome in 23 patients and symptomatic ulnar-plus variance secondary to trauma in 6 patients (4 with previous distal radius fractures, 2 with Essex-Lopresti injuries). The preoperative ulnar variance ranged from +1 mm to +6 mm.

Results: The mean follow-up period was 34 months. All osteotomies healed uneventfully. The mean postoperative ulnar variance was +0.2 mm (range, –1 mm to +1.5 mm). Three patients had hardware removal.

Conclusions: The step-cut osteotomy resulted in solid union in all patients. It provides ample bone-to-bone contact and easier control of rotation, and no special instrumentation is necessary. Stable fixation permitted early mobilization of the wrist and palmar placement of the plate minimized the need for plate removal. This is a simple and effective technique for ulnar shortening. (*J Hand Surg* 2005;30A:943–948. Copyright © 2005 by the American Society for Surgery of the Hand.)

Key words: Osteotomy, step-cut, ulna shortening, ulnar-impaction syndrome.

Extra-articular ulnar shortening is an established procedure for treating ulnar-impaction syndrome. It also is used to treat distal radioulnar joint (DRUJ) derangement secondary to malunions or Essex-Lopresti injuries provided that DRUJ arthritis has not pre-

vailed. Several techniques for this osteotomy have been described in recent years,^{1–11} reflecting the difficulties that sometimes are encountered in what seems to be a relatively simple procedure.

The configuration of the cut usually is either transverse or oblique. Difficulties are encountered with both of these configurations. With transverse osteotomies^{1,2,5–7} the rotation control can be problematic; moreover the cuts must be perfectly parallel to ensure good bone apposition and compression to avoid non-union or malunion. Oblique osteotomies^{3,4,8–11} provide a larger contact surface, facilitating union, but proper alignment still necessitates perfectly parallel cuts and rotation control. Their fixation must follow the principles of antiglide plating¹² and the placement of a lag screw can be difficult. Furthermore the exact amount of shortening achieved is highly dependent on the exact angle of the osteotomy—it can

From the Department of Orthopaedic Surgery, Allegheny General Hospital, Pittsburgh, PA; and the Department of Orthopaedic Surgery, University of Pittsburgh Medical Center, Pittsburgh, PA.

Received for publication February 14, 2005; accepted in revised form May 30, 2005.

No benefits in any form have been received or will be received from a commercial party related directly or indirectly to the subject of this article.

Corresponding author: Dean G. Sotereanos, MD, Allegheny General Hospital, Department of Orthopaedic Surgery, 1307 Federal St, Pittsburgh, PA 15212; e-mail: dsoterea@wpahs.org.

Copyright © 2005 by the American Society for Surgery of the Hand
0363-5023/05/30A05-0009\$30.00/0
doi:10.1016/j.jhsa.2005.05.010

be as much as double the size of the wafer of bone removed for a 60° osteotomy.⁴

Several devices that can facilitate these osteotomies have been described. Single-cut osteotomies with multiple blades mounted on the power saw⁴ ensure parallel cuts, but the amount of shortening still depends on the angle of the cut and multiple blade sizes must be available to accommodate different amounts of shortening. Shortening by using the compression features of the limited contact-dynamic compression plate applied before the osteotomy¹¹ is complicated and limits shortening to a maximum of 2.5 mm. A long oblique osteotomy made with a specialized jig¹⁰ allows control over the amount of shortening but translation of the bone ends can be problematic with larger shortenings. Fixation of the long oblique osteotomy with only 4 screws is not as secure as plate fixation and requires longer protection. The use of external fixation devices to control rotation and facilitate reduction in transverse osteotomies has been proposed^{3,5} but these do not solve the problem of parallel cuts and involve a learning curve.

Dedicated ulnar-shortening devices also have been described.^{3,8} These provide parallel cuts that are accurate both in width and in angle but they require specialized equipment (eg, jigs,^{3,8} plates³). Because of the bulky jigs that must be used volar placement of the plate (which is desired to avoid extensor tendon irritation caused by attrition) is difficult.

Bowers¹³ alluded to the use of a step-cut osteotomy for ulnar shortening. The step-cut configuration offers larger contact surfaces compared with transverse osteotomies and better control of rotation. With appropriate surgical technique accurate shortening can be performed freehand. The technique we use for step-cut ulnar shortening places the long arm of the step-cut in the coronal plane and the short arms perpendicular to that in the axial plane (Fig. 1A), and stable fixation can be achieved with a lag screw and a volarly placed 3.5-mm neutralization plate. Volar placement of the plate avoids extensor tendon irritation. The osteotomy can be designed reproducibly using the 3.5-mm plate as a template.

In this study we present our technique and results with a step-cut ulnar-shortening osteotomy.

Materials and Methods

From 2000 to 2003, there were 29 consecutive patients (13 male, 16 female) with a mean age of 35.3 years (range, 14–55 y) who had a step-cut ulnar-shortening osteotomy performed by the senior author

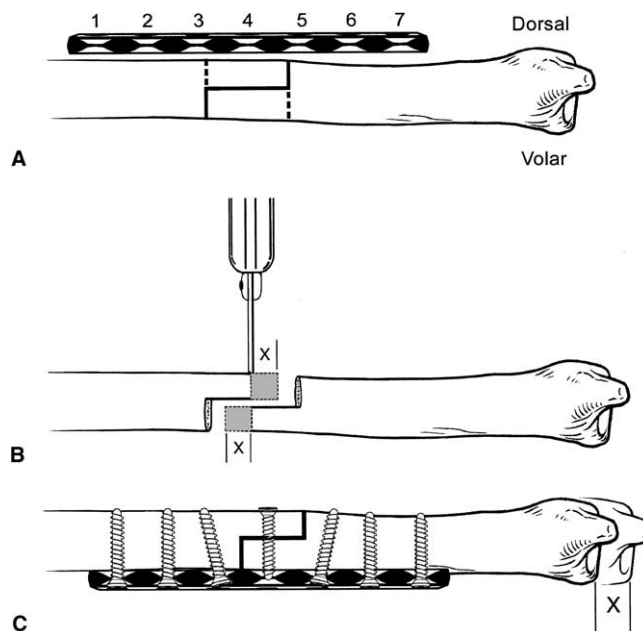


Figure 1. (A) A 3.5-mm 7-hole AO plate is used as a template for the osteotomy. The step-cut is designed to extend between the third and fifth holes of the plate. (B) After completing the initial cuts the intended length of shortening is marked and cut on both the proximal and distal osteotomy arms. (C) After reduction a dorsal-to-volar lag screw first is placed to compress the arms of the osteotomy. A volarly placed 3.5-mm AO neutralization plate is applied next.

(D.G.S.). The records of those patients were reviewed retrospectively after obtaining institutional review board approval. The indication was ulnar-impaction syndrome in 23 patients and symptomatic ulna-plus variance secondary to trauma in 6 patients (4 with previous distal radius fractures, 2 with Essex-Lopresti injuries). The preoperative ulnar variance averaged +2.7 mm and ranged from +1 to +6 mm (+1 to +4 mm in the ulnocarpal-impaction group). Ulnar variance was assessed radiographically with the pronated grip view¹⁴ in all patients. Fourteen patients had previous procedures performed including distal radius fracture open reduction internal fixation in 1, radial head excision and DRUJ pinning in 2, arthroscopic triangular fibrocartilage complex debridement in 8, and arthroscopic wafer procedures in 3. Eleven of the patients systematically used tobacco products. The goal of the osteotomy was to reduce ulnar variance to neutral or to -1 mm. In posttraumatic cases with distorted anatomy, slight (1–2 mm) postoperative ulnar-positive variance was allowed if correction to neutral would cause DRUJ incongruence.

Wrist arthroscopy before ulnar shortening was performed in the same setting in 19 of the 29 patients.

Wrist arthroscopy was performed if after clinical examination and imaging studies there still were questions regarding the diagnosis of ulnar impaction or if other intra-articular pathology was noted. We used arthroscopy before ulnar shortening to confirm the diagnosis or address the intra-articular pathology (unstable triangular fibrocartilage complex flaps, chondral flaps, partial scapholunate or lunotriquetral ligament lesions).

Surgical Technique

The procedure may be performed with the arm suspended from a traction tower if wrist arthroscopy is performed before ulnar shortening. Nineteen of the procedures were performed in this position. Alternatively the procedure can be performed with the arm lying on the armboard (with the shoulder abducted, the elbow flexed, and the forearm fully pronated). Through an 8-cm incision slightly volar to the subcutaneous border of the distal third of the ulna, access to the bone is obtained after dissecting the interval between the extensor carpi ulnaris and the flexor carpi ulnaris. The periosteum is elevated only at the intended site of the osteotomy for 2 to 3 cm. The ulnar artery and nerve are protected with small Homan retractors.

The step-cut osteotomy has its long arm oriented in the coronal plane parallel to the long axis of the ulna. The short arms of the osteotomy are perpendicular to the long axis in the axial plane (ie, volar to dorsal and dorsal to volar) (Fig. 1A). To facilitate designing the osteotomy a 7-hole 3.5-mm dynamic compression plate (Synthes, Paoli, PA) is apposed to the ulna (Fig. 1A). The plate should be placed proximal enough that neither the plate nor the distal screws will impinge into the DRUJ with forearm rotation. The osteotomy, approximately 2 cm in length, is designed to extend from the third to the fifth holes of the plate, making sure that there is room left for bicortical screw placement in these 2 holes. In most situations a 2- to 4-mm shortening of the ulna is desired, and use of the 7-hole plate as a template ensures that the arms of the step-cut will have sufficient length for lag-screw placement after shortening. If an unusual amount of ulnar shortening is intended the osteotomy can be designed between the third and sixth holes of an 8-hole plate, thus creating longer arms. The planed osteotomy is outlined on the cortex of the ulna with a marking pen and the plate is removed from the field.

The long arm of the osteotomy is cut first using an oscillating saw. Care is taken to orient this cut in a

medial-to-lateral (coronal plane) direction and to cut both cortices. The 2 short arms are cut next in the axial plane perpendicular to the first cut. Next the intended length of shortening is marked on both the proximal and distal osteotomy arms (Fig. 1B). Note that the full amount of shortening (not half of it) must be marked on both arms. A close approximation of the precise shortening can be achieved by subtracting 1 mm from the intended shortening to account for saw kerf width and marking that length on the osteotomy arms. The bone is removed by cutting parallel to the short arms of the osteotomy. The 2 wafers of bone that are removed then are compared and measured, with corrections made if necessary.

The osteotomy then is reduced. Ulnar deviation of the wrist facilitates approximation of the bone ends. Once reduction is deemed satisfactory it is secured with a reduction clamp across the osteotomy, with care taken to leave room for lag screw placement. A lag screw then is drilled and inserted from dorsal to volar perpendicular to the long arm of the osteotomy (Fig. 1C). Finally the 7-hole dynamic compression plate is placed on the volar flat surface of the ulna and centered on the osteotomy (the fourth hole of the plate being opposite to the lag screw). Three screws are inserted on each side of the osteotomy in the neutralization mode. The 2 screws adjacent to the osteotomy are angled slightly away from the osteotomy to avoid insertion through the osteotomy site. The fixation technique can be modified so that compression is applied through the plate as well. In that case the plate is applied first, the osteotomy is compressed longitudinally, and then the lag screw compressing the long arm of the osteotomy is inserted through the plate. We find the latter technique to be more cumbersome. Before closure the tourniquet is released, local bleeding is controlled, and the wound is irrigated.

A short-arm plaster splint is applied and is replaced with a removable thermoplast splint at the time of suture removal in 2 weeks. Removal of the thermoplast splint is allowed for hygiene and gentle range of motion exercises. Unprotected range of motion is initiated at 6 weeks but weight bearing is avoided until clinical and radiologic union.

The preoperative and postoperative office notes and radiographs of all patients were reviewed. Typically a pronated grip view was obtained for all patients at 6 weeks and the postoperative ulnar variance was assessed from those radiographs. The amount of shortening was measured by comparing preoperative and postoperative posteroanterior pro-

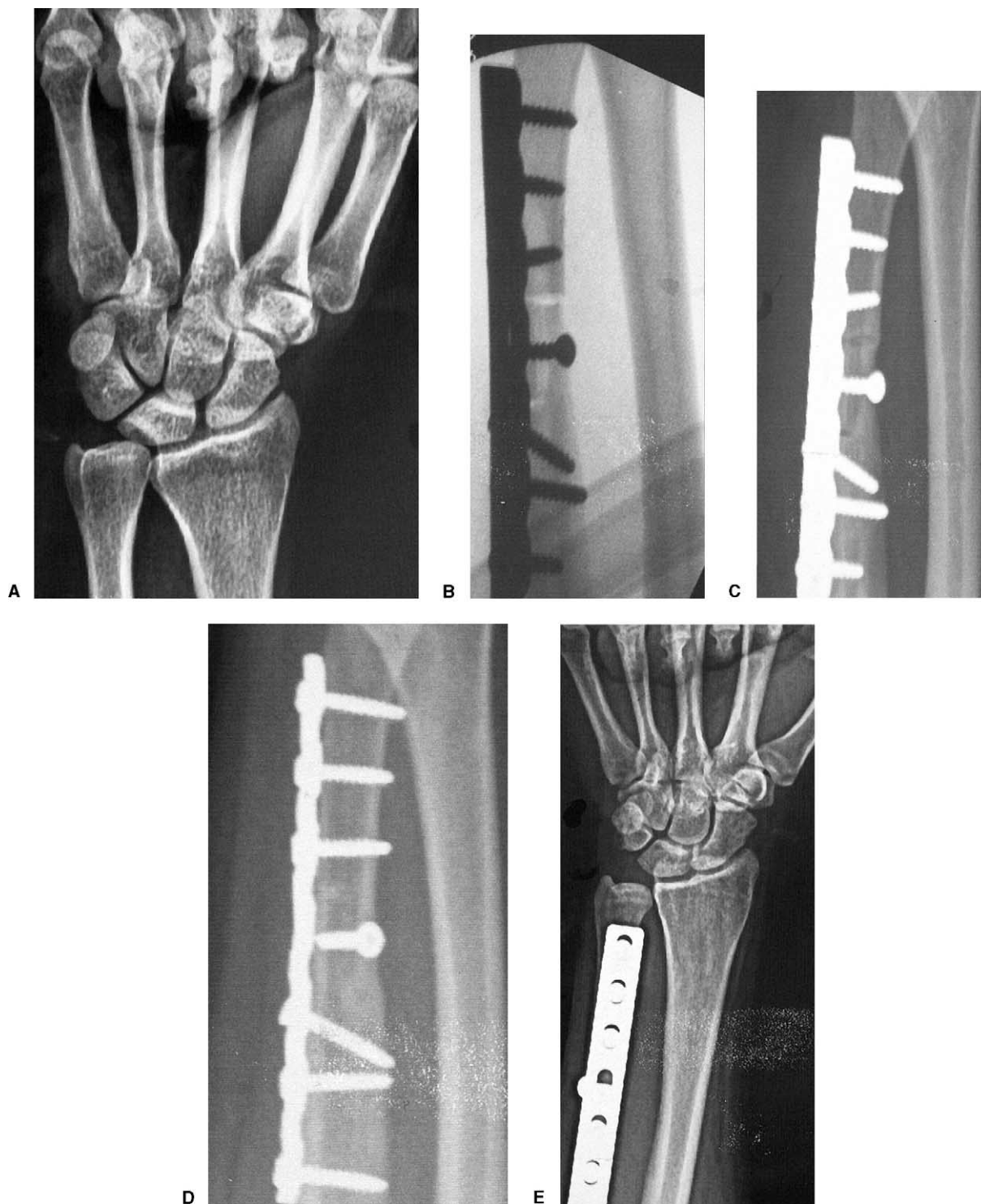

Figure 2. (A) Preoperative pronated grip view radiograph of a patient with ulnocarpal impaction. The cystic kissing lesion at the ulnar side of the lunate can be observed. Progression of healing of the step-cut osteotomy on oblique-view radiographs of the same patient: (B) intraoperative, (C) at 6 weeks, and (D) at 10 weeks. (E) Postoperative pronated grip-view radiographs showing correction of ulnar variance.

nated grip view radiographs. Oblique views were obtained to assess the progression of healing because the plate obstructs the view to the osteotomy site in lateral radiographs obtained in a routine fashion.

Union was defined as blurring of the cortical margins of osteotomy and trabecular bone bridging the osteotomy site³ in conjunction with absence of tenderness at the osteotomy site (clinical union). Because

of the osteotomy and fixation techniques used, primary bone healing usually ensued along the long arm of the osteotomy without visible callus formation. The incidence of union, time to union, and complications and incidence of plate removal were recorded.

Results

All patients had a follow-up period of at least 1 year (mean, 34 mo; range, 12–48 mo). All osteotomies healed uneventfully with a mean time to union of 8.3 weeks (range, 6–18 wk) (Fig. 2). In 1 patient radiographic healing of the proximal short arm of the osteotomy was observed at 18 weeks whereas both the long arm and distal short arm appeared healed by 10 weeks. No additional measures were taken to achieve union in that case. Union was observed within 12 weeks in all other patients. No cases of nonunion or delayed union were encountered. Bone graft was not used in any of the patients.

The mean postoperative ulnar variance was +0.2 mm (range, –1 to +1.5 mm) after a mean overall shortening of 2.5 mm. The mean ulnar shortening was 2.8 mm (range, 2–5 mm) for the traumatic group and 2.4 mm (range, 2–4 mm) for the ulnar-impaction group.

Persistent plate-related symptoms necessitated hardware removal in 3 patients. The plates were removed after a minimum of 16 months after the procedure. No other complications occurred.

Discussion

We describe a simple and effective technique for ulnar-shortening osteotomy. The step-cut osteotomy resulted in solid union in all patients with no cases of delayed union or nonunion.

Both nonunions and delayed unions have been reported for ulnar-shortening osteotomies^{1,3,6,15–17} with rates up to 15%.¹⁵ The transverse osteotomy configuration^{3,15} and smoking¹⁸ have been considered predisposing factors. Comparison of the time to union between reports is difficult because of differences in the definition of union. Regardless of the differences in the definition it seems that ulnar osteotomy union must be expected within a 5-month time frame.^{1,3,5} All of our patients had well-healed osteotomies by that time (even patients using tobacco products) and the mean time to union of 8.3 weeks compares favorably with other reports.

Plate prominence and irritation can be reasons for reoperation because of the subcutaneous position of the ulna. Hardware removal rates ranging from 25%⁸

to 88%⁵ have been reported. Fractures after plate removal also have been reported.^{7,8} With the technique described in this article, the plate is placed on the volar surface of the ulna where soft-tissue coverage is better. This led to a decreased rate of plate removal (10% at a minimum follow-up period of 1 year) while maintaining the advantages of rigid plate fixation. Palmar placement of the plate can be difficult with techniques that use specialized bulky jigs when more extensive periosteal stripping is necessary to apply the jig.

Friedman and Palmer¹⁹ suggested shortening the ulna to neutral or –1 mm. Shortening of more than –2 mm may lead to DRUJ incongruence. Shortening was accurate in all of our patients in the ulnar-impaction group based on these guidelines.

The step-cut configuration is an excellent option for extra-articular ulnar-shortening osteotomies. It provides ample bone-to-bone contact area and easy control of rotation; no special instrumentation is necessary. Fixation with a 7-hole 3.5-mm dynamic compression plate and a lag screw proved to be sufficient to permit early mobilization of the wrist and palmar placement of the plate minimized the need for plate removal caused by irritation. This technique accurately restored ulnar variance with minimal complications. It facilitates simple and reproducible shortening without the use of special equipment.

References

1. Darrow JC Jr, Linscheid RL, Dobyns JH, Mann JM 3rd, Wood MB, Beckenbaugh RD. Distal ulnar recession for disorders of the distal radioulnar joint. *J Hand Surg* 1985; 10A:482–491.
2. Boulas HJ, Milek MA. Ulnar shortening for tears of the triangular fibrocartilaginous complex. *J Hand Surg* 1990; 15A:415–420.
3. Rayhack JM, Gasser SI, Latta LL, Ouellette EA, Milne EL. Precision oblique osteotomy for shortening of the ulna. *J Hand Surg* 1993;18A:908–918.
4. Labosky DA, Waggy CA. Oblique ulnar shortening osteotomy by a single saw cut. *J Hand Surg* 1996;21A:48–59.
5. Wehbé MA, Cautilli DA. Ulnar shortening using the AO small distractor. *J Hand Surg* 1995;20A:959–964.
6. Hulsizer D, Weiss APC, Akelman E. Ulnar-shortening osteotomy after failed arthroscopic debridement of the triangular fibrocartilage complex. *J Hand Surg* 1997;22A:694–698.
7. Minami A, Kato H. Ulnar shortening for triangular fibrocartilage complex tears associated with ulnar positive variance. *J Hand Surg* 1998;23A:904–908.
8. Mizuseki T, Tsuge K, Ikuta Y. Precise ulnar-shortening osteotomy with a new device. *J Hand Surg* 2001;26A:931–939.
9. Chen NC, Wolfe SW. Ulna shortening osteotomy using a compression device. *J Hand Surg* 2003;28A:88–93.

10. Horn PC. The long ulnar sliding osteotomy. *J Hand Surg* 2004;29A:871–876.
11. Chennagiri R, Burge P. Pre-osteotomy plate application technique for ulnar shortening. *J Hand Surg* 2004;29B:453–457.
12. Khan MI. Comments inspired by two letters on ulnar shortening osteotomy for ulnar impaction syndrome. *J Hand Surg* 1994;19A:871–872.
13. Bowers WH. The distal radioulnar joint. In: Green DP, Hotchkiss RN, Pederson WC, eds. *Green's operative hand surgery*. 4th ed. Philadelphia: Churchill Livingstone, 1999:1017.
14. Tomaino MM. The importance of the pronated grip x-ray view in evaluating ulnar variance. *J Hand Surg* 2000;25A:352–357.
15. Köppel M, Hargreaves IC, Herbert TJ. Ulnar shortening osteotomy for ulnar carpal instability and ulnar carpal impaction. *J Hand Surg* 1997;22B:451–456.
16. Loh YC, Van Den Abbeele K, Stanley JK, Trail IA. The results of ulnar shortening for ulnar impaction syndrome. *J Hand Surg* 1999;24B:316–320.
17. Scheker LR, Severo A. Ulnar shortening for the treatment of early post-traumatic osteoarthritis at the distal radioulnar joint. *J Hand Surg* 2001;26B:41–44.
18. Chen F, Osterman AL, Mahony K. Smoking and bony union after ulnar-shortening osteotomy. *Am J Orthop* 2001;30:486–489.
19. Friedman SL, Palmer AK. The ulnar impaction syndrome. *Hand Clin* 1991;7:295–310.